
Case Report

Gardner's Syndrome Presenting with Dental Complaints

Mansoor Madani DMD MD*, Farideh Madani DMD**

Dental professionals play an important role in discovering the early signs of many illnesses. Gardner's syndrome, which affects one in 7500 births in the United States, is an inherited autosomal dominant disorder. There are three distinctive features associated with this syndrome: familial intestinal polyposis or adenomatosis, surface tumors of hard tissues particularly osteoma in the skull, maxillae, and mandible, and finally surface tumors of the soft tissue. The intestinal polyps have a 100% risk of undergoing malignant transformation if not treated. Consequently, early identification of the disease is critical. In this article an 18-year-old male patient with previously undiagnosed Gardner's syndrome who presented for removal of multiple impacted and unerupted teeth is reported to illustrate the importance of early detection and proper referral. This report describes an unusual presentation of a patient seeking extraction of teeth only, while he was totally unaware of potentially deadly situation.

Archives of Iranian Medicine, Volume 10, Number 4, 2007: 535 – 539.

Keywords: Colon cancer • familial adenomatosis polyposis • Gardner's syndrome • gastrointestinal polyps • impacted teeth

Introduction

Gardner's syndrome is a variant of familial adenomatosis polyposis (FAP), which affects one in 8300 individuals and one in 7500 births in the United States.¹⁻² It is characterized by polyps of the colon, multiple osteomas, and multiple impacted or unerupted teeth, with skin and soft tissue tumors. Cutaneous findings include epidermoid cysts, desmoid tumors, and other benign tumors. Devic and Bussy first described Gardner's syndrome in 1912 as a triad of intestinal polyposis, various soft tissue tumors such as fibromas, lipomas, neurofibromas, and epidermoid cysts, and multiple osteomas especially of the skull.³ Gardner and coworkers identified that this condition was transmitted as an autosomal dominant with nearly complete penetrance but markedly variable expressions.⁴⁻⁶

Dukes was the first to postulate that carcinomas of the colon and rectum were derived from adenomas.⁷ Jackson and Mayo were the first to describe the adenoma-to-carcinoma sequence in 1951.⁸ In 1962 Gardner discovered that these patients also had dental anomalies, and generalized skeletal changes as well as desmoid changes.⁹

Dental anomalies are present in estimated 70% of all affected individuals. These abnormalities include impacted or unerupted teeth, congenitally missing teeth, supernumerary teeth, hypercementosis, dentigerous cyst, fused roots of the first and second molars, long and tapered roots of posterior teeth, and multiple caries.¹⁰

Presence of osteomas is required to make the diagnosis of Gardner's syndrome. The mandible is the most common location, however, osteomas may occur in the skull and the long bones.¹¹ Osteomas precede the clinical and radiographic evidence of colonic polyposis or Gardner's syndrome, therefore, they may be sensitive markers for the disease.

The most common cutaneous finding in patients with Gardner's syndrome is epidermoid cysts, which tend to be numerous and are present in the multiple forms in 50 – 65% of the patients.¹² They may occur on the extremities, face, and scalp and

Authors' affiliations: *Department of Oral and Maxillofacial Surgery, Capital Health Medical Center, Trenton, NJ, Canada, **Oral Medicine, University of Pennsylvania, School of Dental Medicine, Philadelphia, PA, USA.

Corresponding author and reprints: Mansoor Madani DMD MD, Center for Corrective Jaw Surgery, 15 North Presidential Boulevard, Suite 301, Bala Cynwyd, PA 19004.

Tel:+1-610-667-4455, Fax:+1-610-617-9275,
E-mail: drmadani@snorenet.com.

Accepted for publication: 8 April 2007

may occur prior to or after the diagnosis of FAP or Gardner's syndrome.

Several factors differentiate cutaneous cysts associated with Gardner's syndrome from ordinary cysts. Firstly, these lesions occur at an earlier age than ordinary cysts, which occur around puberty. They also appear in less common locations, such as the face, the scalp, and the extremities. Similar to epidermal inclusion cysts, the cysts in Gardner's syndrome are usually asymptomatic, however, they may become purulent and/or inflamed, and they may rupture. Other skin signs include presence of fibromas, lipomas, leiomyomas, neurofibromas, or pigmented skin lesions.¹³⁻¹⁵

Gastric fundic gland polyps occur in approximately 90% of affected individuals. Most of these lesions are hyperplastic and carry no malignant potential. However, adenomatous polyps and their progression to gastric cancer have been observed but are extremely rare.¹⁶

Duodenal polyps occur in up to 90% of all affected individuals. If the polyps become very large, they may cause intestinal bleeding, intussusception, or intestinal blockage. Otherwise, they may not cause any symptoms. Duodenal polyps have a predilection for the periampullary region and are premalignant lesions for periampullary carcinoma. The mortality rate for periampullary carcinoma in patients with Gardner's syndrome is approximately 20 – 25%. The risk is 300 times higher compared with the general population.

Several cases of cholangiocarcinoma and FAP have been reported, which carries a more severe prognosis. Patients with periampullary lesions may present with abdominal pain, emesis, bleeding, and gastric or biliary obstruction manifesting as jaundice. Duodenal polyps in persons with Gardner's syndrome have also been associated with pancreatitis secondary to obstructing the ampulla of Vater by the polyps. The intestinal polyps usually appear by the early to mid teenage years. By age 35, almost all with this disease will have polyps.

Case Report

An 18-year-old male patient was initially visited on May 1994 by his family physician for a large palpable mass on the right side of his face (Figure 1). He was referred for radiographic evaluation to a local hospital and was reported of having a 0.7×1.0 cm calcification/projection of the

inferior aspect of the right angle of the mandible. The radiologist's impression was "a benign soft tissue calcification or osteoma of unknown cause or unusual exostosis". No further evaluation was done on this lesion.

Two years later the patient was visited by his dentist with chief complaint of retained deciduous teeth and severe crowding and malocclusion. The patient was sent to an orthodontist for consultation and orthodontic treatment. He was then referred to a local oral and maxillofacial surgeon for extraction of impacted teeth and removal of deciduous teeth in preparation for orthodontics. Following discussions regarding his extraction he was scheduled for removal of teeth in the operating room. A medical consultation with the patient's primary physician and his concern about hospital-based general anesthesia led the patient to our center seeking outpatient procedure. Following initial evaluation, a panoramic radiograph was obtained (Figure 2). It revealed multiple impacted and unerupted teeth as well as retained deciduous teeth in all quadrants of his jaws. Additionally, areas of dense radio-opacity were noted in the areas apical to the roots of all mandibular teeth as well as maxillary molar and premolar teeth. On the right mandible a very large osteoma was noted as well.

Upon further examination, the patient had multiple soft to firm swellings of varying sizes on the skull. The bony lumps were fixed to the underlying skeleton (osteoma) and the soft masses were fluctuant and cystic in nature (epidermoid inclusion cyst). These swellings had been present for at least three years. The patient reported that he had been going to his primary physician who had been draining the cystic lesions. The patient

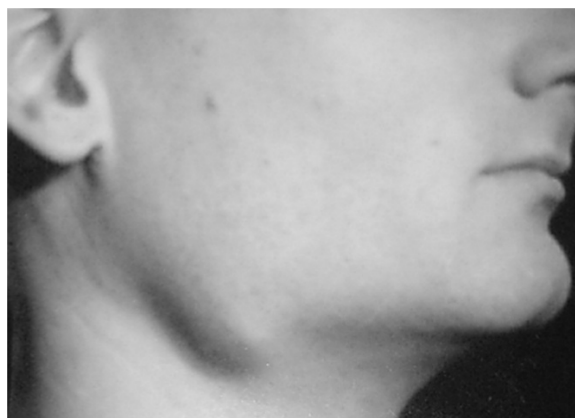

Figure 1. Initial presentation was significant for extra-oral osteoma and multiple sebaceous cysts and osteoma of the skull.

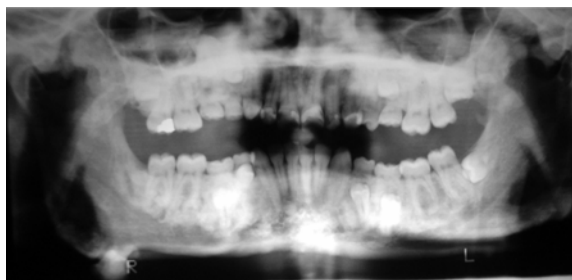
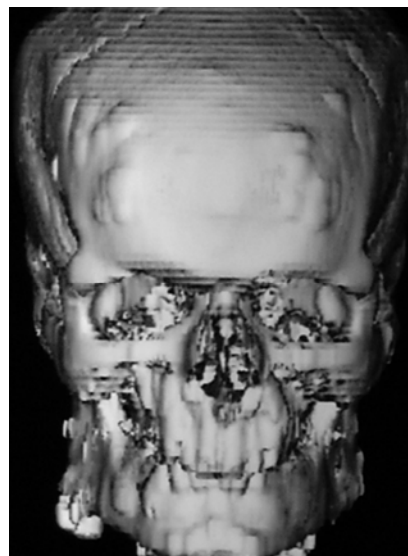


Figure 2. Panoramic radiograph shows multiple unerupted teeth, impacted teeth, and osteoma of the right angle of the mandible and various areas of the mandible and maxillae.

denied having any other systemic problems. There were no histories of diarrhea, nausea, vomiting, recurrent sinusitis, or altered vision. Neurologic examination and the rest of the systemic examination was normal. No other individual in the family had similar swellings or have been diagnosed of having gastrointestinal problems or died from cancer.

Although the patient had no family history of major illnesses or disorders, based upon our observations of multiple osteomas, sebaceous cysts, and the dental findings, he was advised to be evaluated by a gastrointestinal specialist for intestinal polyps to rule out Gardner's syndrome, prior to any extraction. The patient had a colonoscopy done within a week after our recommendations, which revealed numerous polyps (tubular adenoma) without evidence of malignancy. A month later he had a total abdominal colectomy with ileo-distal sigmoid anastomosis.

Computed tomography (CT) of the head and neck regions, chest radiography, electrocardiography, and complete blood tests were ordered and obtained. The standard as well as three-dimensional reconstruction of CT clearly revealed the presence of multiple osteoma of the skull and the extracranial extension of the osteoma without compression of the brain parenchyma (Figure 3). The brain parenchyma was normal and did not show any focal area of abnormal attenuation. CT scans also demonstrated sclerotic bony overgrowth of osteomas in the pterygoid plates (Figure 4). The osteoma from the right mandible and several of the large temporal cysts were excised for cosmetic reasons. Pathologic diagnosis confirmed benign dense lamellar osteoma without hematopoietic bone marrow or fibrosis and epidermoid inclusion cysts of temple area. At the time of that procedure the patient decided to wait for removal of teeth, as they were



Figures 3. Three-dimensional reconstruction CT scan demonstrating the osteomas of the skull in the areas of the frontal bone, mandible, maxillae, and to some degree the orbit. Note the large osteoma on the right angle of the mandible.

totally asymptomatic.

The patient has been under close observation for any changes in the head and neck lesions as well as intestinal problems for the last twelve years. On the latest follow-up examination the patient reported that he had been diagnosed of having new intestinal polyps, which will be removed shortly. He also had developed several new sebaceous cysts in his face, which were removed under local anesthesia.

Discussion

Gardner's syndrome is characterized by

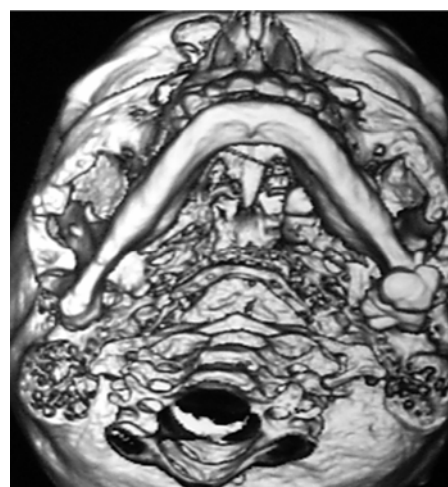


Figure 4. Three-dimensional CT scan showing the involvements of the ramous of the mandible and base of the skull. Note the extension of the osteomas into the sigmoid notch.

colorectal adenomas, multiple osteomas especially of the skull, and various soft-tissue tumors. The disease is inherited as an autosomal dominant disorder. Approximately one third of the cases occur spontaneously and appear to represent new gene mutation.¹ All untreated patients will develop colorectal carcinomas.⁷ Because the clinical and radiologic features in the maxillofacial region, such as osteomas, skin cysts, atypical skin pigmentation, and abnormal dental findings or radiographic lesions can precede the often asymptomatic adenomas for many years,¹¹ dental practitioners and radiologists should be familiar with the manifestations of this syndrome.

This case is reported to illustrate the dentist's role in the diagnosis of Gardner's syndrome. It is proposed that radiologic study of the jaws may serve as a valuable tool for the early detection of carriers of Gardner's syndrome.

The remarkable feature of this patient was the unusual presentation and early manifestations of head and neck lesions. Unlike most patients of Gardner's syndrome who present with gastrointestinal symptoms such as bloody diarrhea and pain in abdomen, our patient presented with dental and facial cosmetic issues. Additionally, no other individual in the patient's family has ever had this disorder. The patient's immediate family members were all examined by the gastroenterologist and were found to be free of any intestinal polyps, suggesting possible gene mutation in this case. Other family members were also examined recently with no findings of any intestinal polyps.

Upon diagnosis of Gardner's syndrome, patient may require consultation with the gastroenterologist for endoscopies, monitoring and surveillance of malignancies, oncologist for treatment of malignancies, and general surgeon for biopsy or resection of suspicious areas such as colon. Dental professionals can play a significant role in early diagnosis, treatment of mandibular or other facial osteomas, and management of impacted or unerupted teeth and cysts of the jaws or face. In addition, ophthalmologist may be consulted for evaluation of retinal anomalies. In presence of thyroid carcinoma and adrenal carcinoma endocrinologist may be consulted as well. Good documentation of radiographic studies to include CT scans and magnetic resonance imaging can help in identifying the extent of lesions and severity of the case.

Management measures include surveillance and

careful follow-up, and colonoscopy to include both upper and lower gastrointestinal area to make sure that cancer does not develop in the stomach or intestine. It is recommended that this examination be repeated every two years. Surgical procedures may include subtotal colectomy with stripping of rectal mucosa and ano-ileal anastomosis and treatment (electrodesiccation) of rectal polyps or in more advanced cases total proctocolectomy with terminal ileostomy.

Generally, cutaneous findings do not require treatment except for cosmetic reasons or biopsies to rule out malignancies. Osteomas may require excision if they are severely deforming or if they interfere with function. Dental managements may include removal of the impacted teeth, cysts of the jaw or face as well as resection of osteomas for functional or cosmetic reasons.

References

- 1 Nandakumar G. Familial polyposis coli: clinical manifestations, evaluation, management, and treatment. *Mt Sinai J Med.* 2004; **71**: 384 – 391.
- 2 Campos FG, Habr-Gama A, Kiss DR, Atui FC, Katayama F, Gama-Rodrigues J. Extracolonic manifestations of familial adenomatous polyposis: incidence and impact on the disease outcome. *Arq Gastroenterol.* 2003; **40**: 92 – 98.
- 3 Devic A, Bussy MM. Un cas de polypose adenomateuse generalisée autour de l'intestine. *Arch Mal Appar Dig.* 1912; **6**: 278 – 299.
- 4 Gardner EJ, Plenk HP. Hereditary patterns for multiple osteomas in a family group. *Am J Hum Genet.* 1952; **4**: 31 – 36.
- 5 Gardner EJ, Richards RC. Multiple cutaneous and subcutaneous lesions occurring simultaneously with hereditary polyposis and osteomatosis. *Am J Hum Genet.* 1953; **5**: 139 – 147.
- 6 Stewart RE, Prescott GH. Dysmorphic syndrome with craniofacial manifestations. In: Stewart RE, Prescott GH. *Oral Facial Genetics.* St. Louis: Mosby; 1976: 594 – 595.
- 7 Dukes CE. The classification of cancer of the rectum. *J Pathol Bacteriol.* 1932; **35**: 323 – 332.
- 8 Mayo LD, Jackson MW. Transformation of adenoma-to-carcinoma sequence in Gardners Syndrome. *Arch Intern Med.* 1951; **87**: 598.
- 9 Gardner EJ. Follow-up study of a family group exhibiting dominant inheritance for a syndrome including intestinal polyps, osteomas, fibromas, and epithelial cysts. *Am J Hum Genet.* 1962; **14**: 376 – 390.
- 10 Shafer WG, Hines MK, Levy BM. *A Textbook of Oral Pathology.* 3rd ed. Philadelphia: W.B. Saunders; 1974: 43 – 44.
- 11 Gorlin RJ, Pindborg JJ, Cohen MM. *Syndromes of the Head and Neck.* 2nd ed. New York: McGraw-Hill; 1976: 324 – 328.
- 12 Ascari-Raccagni A, Baldari U, Righini MG. Cutaneous

- symptoms of Gardner's syndrome. *J Eur Acad Dermatol Venereol.* 1999; **12**: 80 – 81.
- 13** Marshall KA, Kuhlmann TP, Horowitz JH, Silloway KA, Edlich RF. Excision of multiple epidermal facial cysts in Gardner's syndrome. *Am J Surg.* 1985; **150**: 615 – 616.
- 14** Narisawa Y, Kohda H. Cutaneous cysts of Gardner's syndrome are similar to follicular stem cells. *J Cutan Pathol.* 1995; **22**: 115 – 121.
- 15** Perniciaro C. Gardner's syndrome. *Dermatol Clin.* 1995; **13**: 51 – 56.
- 16** van Epps KJ, Kuszyk BS, Hofmann LV, Fishman EK. Epidermoid inclusion cysts seen on CT of a patient with Gardner's syndrome. *AJR Am J Roentgenol.* 1999; **173**: 858 – 859.